

# Neurology®

## **A network approach to assessing cognition in disorders of consciousness**

D. Rodriguez Moreno, N.D. Schiff, J. Giacino, et al.

*Neurology* 2010;75;1871-1878 Published Online before print October 27, 2010

DOI 10.1212/WNL.0b013e3181feb259

**This information is current as of October 27, 2010**

The online version of this article, along with updated information and services, is located on the World Wide Web at:

<http://www.neurology.org/content/75/21/1871.full.html>

*Neurology*® is the official journal of the American Academy of Neurology. Published continuously since 1951, it is now a weekly with 48 issues per year. Copyright Copyright © 2010 by AAN Enterprises, Inc.. All rights reserved. Print ISSN: 0028-3878. Online ISSN: 1526-632X.



# A network approach to assessing cognition in disorders of consciousness



D. Rodriguez Moreno,  
PhD  
N.D. Schiff, MD  
J. Giacino, PhD  
K. Kalmar, PhD  
J. Hirsch, PhD

Address correspondence and  
reprint requests to Dr. D.  
Rodriguez Moreno or Dr. Hirsch,  
Department of Radiology,  
Functional MRI Research Center,  
Neurological Institute B41, Box  
108, 710 West 168th Street,  
New York, NY 10032  
drmoreno2002@yahoo.com or  
joyhirsch@yahoo.com

## ABSTRACT

**Objective:** Conventional assessments of consciousness rely on motor responses to indicate awareness. However, overt behaviors may be absent or ambiguous in patients with disorders of consciousness (DOC) resulting in underrating capacity for cognition. fMRI during a silent picture-naming task was evaluated as an indicator of command following when conventional methods are not sufficient.

**Methods:** A total of 10 patients with and without conventional evidence of awareness, who met diagnostic criteria for the minimally conscious state (MCS) (n = 5), vegetative state (VS) (n = 3), emerged from MCS (EMCS) (n = 1), and locked-in syndrome (LIS) (n = 1), participated in this observational fMRI study.

**Results:** The LIS and EMCS patients engaged a complete network of essential language-related regions during the object-naming task. The MCS and 2 of the VS patients demonstrated both complete and partial preservation of the object-naming system. Patients who engaged a complete network scored highest on the Coma Recovery Scale-Revised.

**Conclusions:** This study supports the view that fMRI during object naming can elicit brain activations in patients with DOC similar to those observed in healthy subjects during command following, and patients can be stratified by completeness of the engaged neural system. These results suggest that activity of the language network may serve as an indicator of high-level cognition and possibly volitional processes that cannot be discerned through conventional behavioral assessment alone. *Neurology*® 2010;75:1871-1878

## GLOSSARY

**BA** = Brodmann area; **BOLD** = blood oxygenation level-dependent; **CRS-R** = Coma Recovery Scale-Revised; **DOC** = disorders of consciousness; **EMCS** = emerged from minimally conscious state; **GFI(d)** = dorsal inferior frontal gyrus; **GFI(v)** = ventral inferior frontal gyrus; **hrf** = hemodynamic response function; **LIS** = locked-in syndrome; **MCS** = minimally conscious state; **preSMA** = pre-supplementary motor area; **STG** = superior temporal gyrus; **VS** = vegetative state.

Awareness of self or environment is a component of conscious processing and is conventionally assessed by overt motor responses. Using this method, patients who are in minimally conscious state (MCS) demonstrate fluctuations in awareness and clear, but inconsistent, minimal behavioral signs of conscious awareness,<sup>1</sup> and patients in vegetative state (VS) are awake but assumed not aware, because they do not show behavioral responses to environmental stimuli in a contingent manner.<sup>2</sup> On the other hand, patients with LIS (locked-in syndrome) similarly show very limited signs of awareness due to profound sensory and motor deficits but have preserved self-awareness and normal or near-normal cognitive capacities.<sup>3</sup> Thus, impairments of the sensory and motor systems in these patient populations may render conventional bedside diagnosis inadequate and are thought to have contributed to high rates of misdiagnosis of LIS, MCS, and VS<sup>4</sup> as well as underestimation of cognitive capacity. Recent neuroimaging studies using passive tasks,<sup>5-7</sup> imagery tasks,<sup>8-11</sup> and covert tasks<sup>12,13</sup> have suggested that a larger number

Editorial, page 1860

Supplemental data at  
[www.neurology.org](http://www.neurology.org)

*e-Pub ahead of print on October 27, 2010, at [www.neurology.org](http://www.neurology.org).*

From the Departments of Radiology (D.R.M., J.H.), Psychology (J.H.), and Neuroscience (J.H.), Functional MRI Research Center, Neurological Institute B41, New York; Department of Neurology and Neuroscience (N.D.S.), Weill Medical College of Medicine, Cornell University, New York, NY; and JFK Johnson Rehabilitation Institute (J.G., K.K.), Edison, NJ.

**Study funding:** Supported by the NIDRR (H133A070030), the NIH (RO1NS056274), and James S. McDonnell Foundation.

**Disclosure:** Author disclosures are provided at the end of the article.

of patients with disorders of consciousness (DOC) than previously suspected may retain some level of awareness undetected by conventional behavioral response methods.

The goal of this study was to evaluate a silent picture-naming task as a command-following paradigm to assess putative cognitive capacity in patients who fail to demonstrate discernible evidence of awareness on bedside examination. We considered the specificity of brain activity to this task to be a representative index of covert responses by virtue of the distinction between patterns of activity known to be elicited by this task and those elicited by passive viewing.<sup>14-17</sup>

**METHODS Subjects.** All patients entering the brain trauma unit at JFK Johnson Rehabilitation Institute were screened for study eligibility over the course of 3 years. All potentially eligible patients were also recruited at the Weill Cornell Medical Center–New York Presbyterian Hospital. Initial recruitment excluded patients with MRI incompatible devices, contraindications for ambulance transportation, evidence of lesions involving two-thirds or more of Wernicke, Broca, or both areas, and uncontrolled seizure disorders. Seventeen consecutive patients were recruited for this study. Here we report 10 right-handed patients, 5 male, age 18–58 years (mean = 34.4 ± 15.9) (table 1). Seven patients were not included due to 1) severe motion artifacts (1 patient in MCS and 1 patient in EMCS), 2) inability to complete the 2 picture-naming runs due to fatigue, lack of fixation on stimulus, or restlessness (2 patients in MCS and 1 patient in EMCS), 3) severe imaging artifacts due to abnormal brain structure encompassing half or more of an entire

hemisphere (1 patient in VS), or 4) known visual impairments (1 patient in MCS). One patient was diagnosed as in LIS according to Haig et al.,<sup>3</sup> 1 patient met the diagnostic criteria for EMCS,<sup>1</sup> 5 patients met the criteria for MCS,<sup>1</sup> and 3 patients met the criteria for VS set by the American Academy of Neurology.<sup>18</sup> At the time of the scan, the patient with LIS had recovered lateral head movement, right-hand finger movements, vertical eye movements, and consistent, accurate communication.

**Standard protocol approvals and patient consents.** Signed assent from the patient's legal representative was obtained prior to participation in the study in accordance with established institutional guidelines under protocol AAAA-3690. This study was approved by the Institutional Review Boards of Columbia University, the Solaris Health System, and Weill Cornell Medical Center–New York Presbyterian Hospital.

**Imaging.** All scans were collected on a 1.5-T General Electric (LX) magnetic resonance scanner with a standard head coil. Functional scans consisted of 2 axial EPI time series (128 × 128 mm matrix, 21 contiguous slices, field of view = 190 mm, 1.5 × 1.5 × 5 mm voxels, repetition time = 3,000 msec, echo time = 43 msec, flip angle = 60°) obtained parallel to the AC/PC line. A total of 48 images was acquired in each run. Each active condition lasted 40 seconds and was preceded and followed by a resting period of 40 seconds. Conventional high-resolution (T1-weighted) images were also acquired along sagittal planes and at the same axial plane locations as the T2\*-weighted images.

**fMRI paradigm.** The fMRI activation paradigm consisted of 2 separate block runs. The visual stimuli consisted of drawings of objects (Boston Naming Set 2), and stimuli were presented on MRI-compatible goggles (n = 3) or back-projected on a screen (n = 7) depending on patient tolerance. Eye tracking was not possible, as patients are required to perform eye movements to specific locations on command for calibration. However, when

**Table 1** Summary of demographic and clinical information

Patient	Age, y	Sex	Etiology	Lesion site	Time postinjury	Highest-level behavior	CRS-R
LIS	53	M	Pontine tegmentum stroke	Medulla to midbrain	7 mo	Oculomotor command following; visual communication	16/23
EMCS	36	M	TBI following MVA	Brainstem; left temporal; left inferior frontal; left superior frontal	3 y	Motor command following; verbal communication	21/23
MCS1	56	F	Anterior cingulate stroke	Bilateral anterior cingulate	1.5 y	Motor command following; verbal communication	19/23
MCS2	58	F	Fat embolism following orthopedic surgery	Diffuse gray matter injury	2 y	Motor command following; verbal communication	17/23
MCS3	24	F	Midbrain stroke	Midbrain	2 y	Vertical eye movements	10/23
MCS4	19	F	TBI following a fall	Left superior frontal; bilateral occipital; right thalamus	3 mo	Motor command following	10/23
MCS5	35	M	TBI following MVA	Left basal ganglia; right thalamus; right superior frontal	2 mo	Eye opening to tactile stimulation	8/23
VS1	21	M	TBI following MVA	Left medial frontal; left parietal; diffuse volume loss	3 mo	Spontaneous eye-opening; flexion withdrawal	7/23
VS2	18	M	TBI following MVA	Right temporal; bilateral frontal; right basal ganglia	4 mo	Oral movement; flexion withdrawal	7/23
VS3	24	F	Anoxic following near drowning	Diffuse volume loss	7 y	Spontaneous eye-opening; spontaneous blinking	3/23

Abbreviations: CRS-R = Revised Coma Recovery Scale; EMCS = emerged from minimally conscious state; LIS = locked-in syndrome; MCS = minimally conscious state; MVA = motor vehicle accident; TBI = traumatic brain injury; VS = vegetative state.

the goggles were employed, eye fixation was confirmed by inspection of the pupil as shown on the monitor. When back-projection was employed, fixation was monitored by an investigator in the scanner room. Patients were instructed to look at the screen, rest during the presence of a “plus sign,” and silently name the objects as they appeared. The following instructions were given to the patients: “Whenever you see a cross sign, just relax and rest. After a while, you will see pictures of objects on the screen. When you see these objects, name then to yourself.” The instructions for the task were given verbally before each run by an investigator through headphones designed to reduce background scanner noise (Resonance Technology, Inc.). In the case of LIS, all instructions were written to accommodate previously diagnosed auditory processing deficits. Patients performed additional auditory and visual passive paradigms as part of a larger study.

**Statistical analysis.** Image processing and analysis was performed with SPM2 software (Wellcome Department of Imaging Neuroscience, University College, London, UK). Preprocessing steps included motion correction using a sinc interpolation algorithm, and smoothing with a 6-mm full-width-half-maximum Gaussian kernel. The blood oxygenation level–dependent (BOLD) response was represented by a boxcar function for the active epoch that was convolved with the canonical hemodynamic response function (hrf). A 160-second high-pass filter was used to remove low-frequency confounds and an hrf-shaped low-pass filter was used to remove unknown temporal autocorrelations. Motion parameters were included as regressors of no interest. In addition, large motion events were modeled with scan nulling regressors as previously described for epileptic patients.<sup>19</sup> Statistical analysis was based on the general linear model. The design matrices modeled the 2 runs separately. Contrasts were aimed at the identification of activations related to language activity corresponding to signal intensities greater than the baseline. Given that signal amplitude may be reduced in this patient population as in patients with vascular disorders,<sup>20</sup> and all results are reported for each individual patient, we selected a statistical threshold of  $t \geq 2.35$  ( $p = 0.01$  uncorrected), intended to avoid

possible false-negative findings. A minimum cluster size of 10 voxels was used as an extent threshold ( $k$ ). A similar approach is used with some clinical populations where signal variability is large across subjects.<sup>21</sup> For each subject, labeling was performed using the whole-brain analysis. Assignments of anatomic labels for active regions were based on correspondence between the patient’s brain anatomy and the human brain atlas as previously described.<sup>5</sup>

**Behavioral assessment.** The Coma Recovery Scale-Revised (CRS-R)<sup>22</sup> was used for diagnoses. CRS-R consists of 23 items organized in 6 subscales that address arousal, auditory, visual, motor, oromotor/verbal, and communication systems. Each subscale is organized hierarchally, with lower items representing reflexive activity and higher items representing cognitive-based behaviors.

**RESULTS** The picture-naming task is designed to target a network of regions specialized for language functions including Broca area and Wernicke area and medial frontal gyrus (generally on the left hemisphere). Our previous results using the same task in 3 sensory modalities in a group of healthy subjects<sup>21,23</sup> show activity in the bilateral primary visual and association cortices, middle/superior temporal gyrus, left ventral/dorsal inferior frontal gyrus, and medial frontal cortex. We use the reported supramodal pattern of functional activation as the normative areas for internal picture naming. The extent to which the patients in this study show activation in the normative brain regions across all diagnostic categories is presented in table 2 and figure 1.

Because the picture-naming task is a visual task, the presence of visual cortex activation is taken as a prerequisite for successful performance of the task, and all patients reported here activated the visual cortex in response to the visual stimulation. LIS, EMCS, and MCS4 activated the primary visual cortex ( $p = 0.001$ ) bilaterally, and the remaining patients engaged primary visual cortex at  $p = 0.01$  in at least one hemisphere, suggesting that all of the subjects performed the visual encoding of the pictures required for the picture-naming task (table e-1 on the *Neurology*<sup>®</sup> Web site at [www.neurology.org](http://www.neurology.org)). In addition to engagement of early visual cortex, the middle occipital and fusiform gyri associated with object recognition<sup>20</sup> were active in all the patients except VS3.

Activation of left temporal regions expected during naming, which mediate semantic knowledge of the object<sup>24–26</sup> associated with object recognition, was observed in LIS, EMCS, MCS1–MCS5, VS2, and VS3 (STG, table 2 and figure 1). Right temporal activation was also present in EMCS, MCS1, and MCS3, and VS1 showed only right temporal activation.

With the exception of VS1, the left ventral inferior frontal gyrus, thought to be associated with phonologic processing,<sup>26–28</sup> more specifically with retrieval of the object’s name, was activated in all

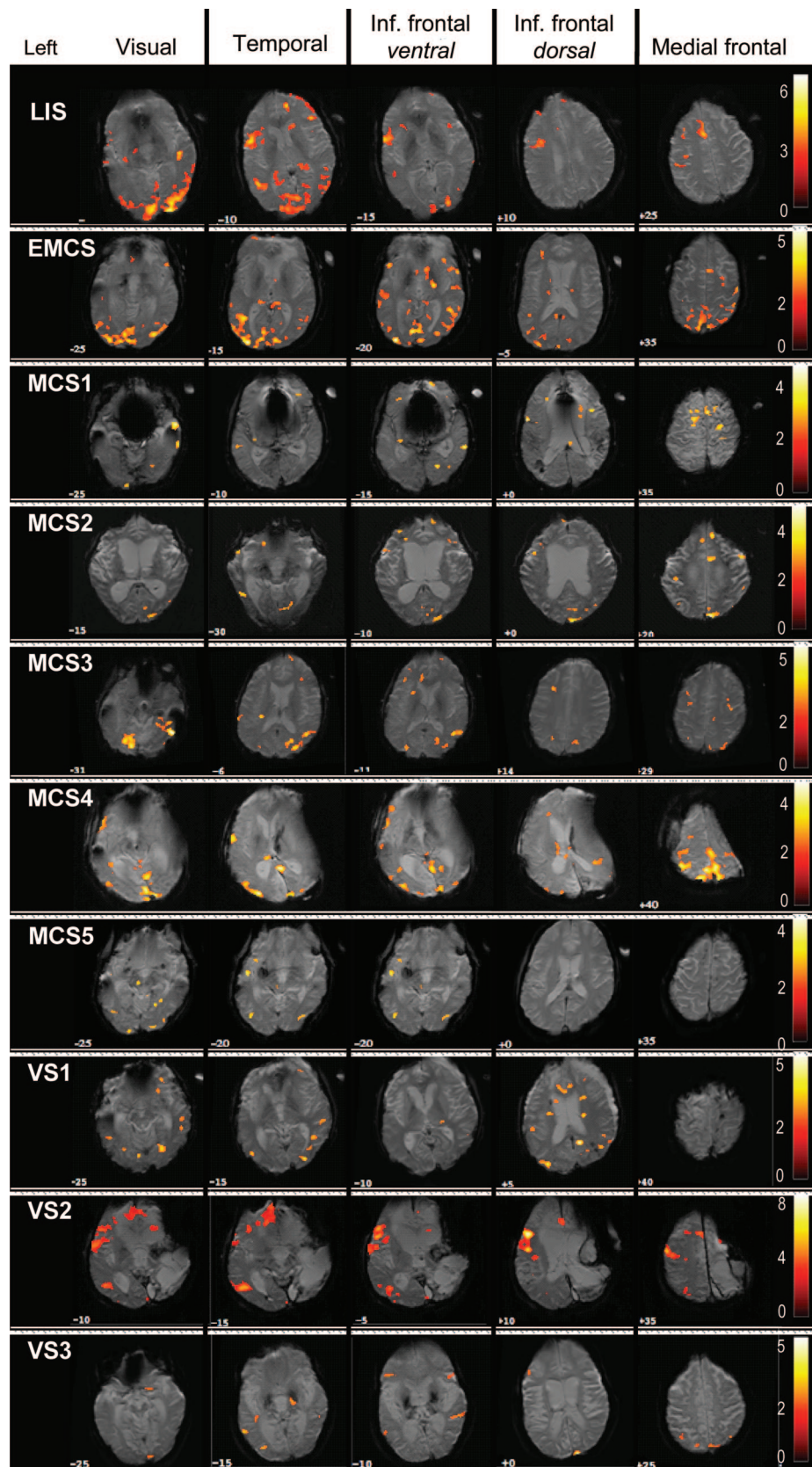
**Table 2**
**Functional activation of normative areas in each patient for the internal picture-naming task and degree of preservation of the naming network**

Patient	Language-sensitive brain areas				Network status
	L STG	L GF <i>i</i> (v)	L GF <i>i</i> (d)	PreSMA	
LIS	✓	✓	✓	✓	Complete
EMCS	✓	✓	✓	✓	Complete
MCS1	✓	✓	✓	✓	Complete
MCS2	✓	✓	✓	✓	Complete
MCS3	✓	✓	✓	—	Partial
MCS4	✓	✓	✓	—	Partial
MCS5	✓	✓	—	—	Partial
VS1	—	—	—	—	Absent
VS2	✓	✓	✓	✓	Complete
VS3	✓	✓	✓	—	Partial

Abbreviations: EMCS = emerged from minimally conscious state; GF*i*(d) = dorsal inferior frontal gyrus; GF*i*(v) = ventral inferior frontal gyrus; LIS = locked-in syndrome; MCS = minimally conscious state; preSMA = pre-supplementary motor area; STG = superior temporal gyrus; VS = vegetative state.

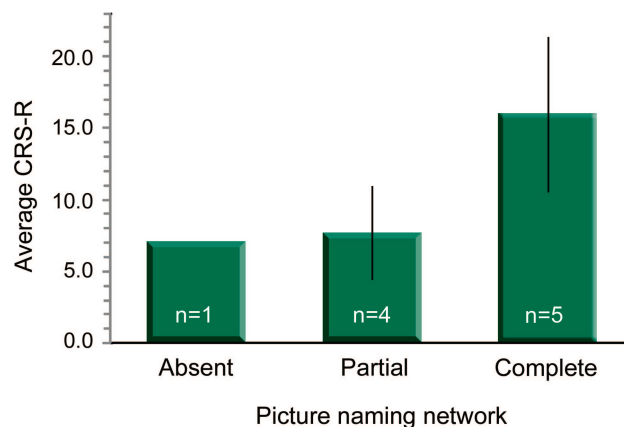


**Figure 1** fMRI results for the covert picture naming for individual patients



Colored voxels indicate blood oxygenation level-dependent (BOLD) responses elicited by the task. Activations are overlaid on each patient's brain and shown in a representative slice for each anatomic area (top row). Color bars reflect the range of BOLD signal intensity changes with corresponding t values. EMCS = emerged from minimally conscious state; LIS = locked-in syndrome; MCS = minimally conscious state; VS = vegetative state.

**Figure 2** Relationship between Revised Coma Recovery Scale (CRS-R) scores and preservation of the picture-naming network



Patients with disorders of consciousness are grouped according to preservation of the naming network previously observed in healthy volunteers: complete network: patients with activation of all brain areas observed in healthy volunteers (left superior temporal gyrus, left ventral inferior frontal gyrus, left dorsal inferior frontal gyrus, and pre-supplementary motor area); partial network: patients with activation of some brain areas observed in healthy volunteers; and 3) absent network: patients with no activation of any brain areas observed in healthy volunteers. The bars show the average CRS-R score for each group with the corresponding SD.

patients (GFi(v), table 2 and figure 1). In addition, LIS, EMCS, MCS1, MCS2, MCS3, VS1, and VS3 activated the right ventral inferior frontal gyrus. Left dorsal inferior frontal gyrus [GFi(d), table 2 and figure 1] is reported to be related to selection of lexical representations<sup>29</sup> and preparation for overt articulation of language<sup>30</sup> and was engaged by LIS, EMCS, MCS1, MCS2, MCS3, MCS4, VS2, and VS3. MCS1 also activated the right hemisphere GFi(d), while VS1 only activated the right hemisphere GFi(d).

Engagement of the pre-supplementary motor area (preSMA) in the medial frontal gyrus, reportedly related to cognitive control<sup>31</sup> and volitional aspects of cognition,<sup>32</sup> was noted in patients with the highest CRS-R scores: LIS, EMCS, MCS1, and MCS2. An exception to this pattern was VS2, who showed activation in left preSMA. We also observed activation of superior frontal gyrus in LIS, MCS1, and VS1 (table e-1).

Our data demonstrate variations in underlying brain activity of the MCS patients for the command-following task (figure 2). The comparison of the naming network observed in healthy volunteers with our patients with DOC suggests a functional differentiation of patients into 3 groups: 1) complete network: patients with activation of all brain areas observed in healthy volunteers; 2) partial network: patients with activation of some brain areas observed in healthy volunteers; and 3) absent network: patients with no activation of any brain areas observed in healthy volunteers. This classification is shown in

the last column of table 2. Our findings show that these neural categories can be generally related to behavioral measures of status. As expected, patients with high CRS-R scores, including LIS, EMCS, MCS1, and MCS2, show a pattern of activity similar to those of healthy subjects elicited by picture-naming task (complete network group). Conversely, patients with low CRS-R scores, i.e., VS1, show a very unresponsive brain as expected for this population (absent network group). Remarkably, patients in the partial network group are characterized by lack of activation in the medial frontal gyrus and lower CRS-R scores, i.e., MCS3 to MCS5.

Nonetheless, we do not observe a strict correspondence between behavioral profile and overall brain activation in agreement with previous studies of language comprehension in patients with DOC.<sup>6-7</sup> Two patients in VS present evidence for some preserved picture-naming activity similar to controls (VS2 in the complete network group and VS3 in the partial network group).

**DISCUSSION** In this study, we employed fMRI during covert picture naming (internal speech) as a command-following task in a series of patients with a range of DOC and behavioral profiles. We observed complete networks expected for the object-naming task in the LIS patient and the EMCS patient, in 2 of the 5 MCS patients, and 1 of the 3 VS patients. These findings demonstrate apparent preservation of some command-following capacity in patients with minimal or no signs of awareness as evidenced by the conventional behavioral examination. Nonetheless, even with these exceptions, we demonstrate a general correspondence between the integrity of the language-specific network and the bedside assessment (CRS-R). These data suggest that fMRI during object-naming tasks may provide additional insight regarding cognitive status for patients with compromised ability to respond by conventional methods.

Picture naming is considered a complex process that recruits both stimulus-driven (bottom-up)<sup>33</sup> and purpose-driven (top-down)<sup>34</sup> pathways including visual input, language, short-term memory, and motor and executive functions. Using a supramodal approach, we previously reported that this task recruited activity in the superior temporal gyrus Brodmann area (BA) 22 (including Wernicke area), inferior frontal gyrus BA 44/45 (including Broca area), and medial frontal gyrus (pre-SMA, BA 6/8).<sup>21,23</sup> Similar patterns of activity have also been reported by other groups and including parietal regions BA 39/40.<sup>35-37</sup> These regions are thought to form a complete long-range network during picture naming. The left BA 22 of the superior temporal

gyrus, also referred to as Wernicke area, has been associated with semantic knowledge<sup>24-26</sup> and phonologic code retrieval<sup>36</sup>; the left ventral region of the inferior frontal gyrus, BA 44/45, has been linked to phonologic processing,<sup>27</sup> selection of competing semantic representations,<sup>28</sup> and phonetic sequencing<sup>37</sup>; and dorsal BA 44/46 has been associated with executive processes to select a lexical representation<sup>29</sup> and processes related to motor programming and planning of articulation.<sup>30</sup> Previous imaging reports have associated frontal midline regions with cognitive control<sup>31</sup> and volitional actions.<sup>9,12,32</sup> Although emphasis has been commonly placed in the linguistic aspects of picture naming, here we used it as a probe of command following.

Although passive viewing of objects is known to recruit occipital and temporal lobe areas,<sup>38</sup> the active task of naming adds an additional load to the neural circuitry that engages other frontal regions and presumptive attention-related resources. In this study, we observed the expected automatic perceptual and object recognition areas during viewing plus the naming-related areas that involve the use of controlled attentional resources.<sup>34</sup> Our observations are consistent with previous EEG, magnetoencephalography, and fMRI studies that have reported brain signals limited to occipital and temporal areas associated with object perception and recognition during passive viewing, and have shown that activity extends to frontal regions during covert and overt picture naming distinguishing the active task from passive viewing.<sup>14-16</sup>

The comparison of naming networks with patients and healthy volunteers allows a classification of patients into 3 categories: patients who retain all components of the reference network (complete network), patients who engage only some of those brain regions (partial network), and patients who show no activation of any of those components (absent network). For the MCS cohort, activation of neural networks associated with language contrasts with the lack of consistent verbal expression in these patients. The results for the VS cohort suggest that even behaviorally unresponsive patients who typically score low in the CRS-R can show signs of awareness using this technique. The finding of unresponsiveness at the behavioral level accompanied by extensive preservation of cognitive networks, as in VS2, challenges our convention to identify VS by behavioral assessment alone in some patients and documents a need for further evaluation of these patients.

Given that picture naming is a nonautomatic (effortful) process,<sup>39</sup> the observation of expected patterns of activity suggests preserved command-following capacities in these patients. The general correspondence to CRS-R measures suggest that

neural correlates of object naming can be used as an index of cognitive capacity when motor responses are not sufficient. The engagement of the naming network may suggest at least partial preservation of purposeful behavior. However, we cannot rule out that neural reorganization in some cases may have occurred outside the naming network in patients who have been injured long before the study. The full extent to which the volitional capacity of patients with DOC can be equated to the experience of awareness in healthy volunteers remains a topic for further investigation.

The high proportion of patients who retain brain activations suggestive of command-following capacity (3 of the 8 patients who remain in a DOC state) in our study in comparison to previous studies using other imagery tasks may suggest that the recovery of language capacities antecedes other observed brain or behavioral responses. Alternatively, it could be that the use of visual activity as inclusion criterion biases our sample toward patients with this ability or that motor-compromised patients have more difficulty with gross motor imagery tasks. Importantly, assessing the integrity of the expressive language system may provide a proxy for the capacity to harness assistive communication systems, although our data do not directly address this possibility.

Command-following paradigms have a number of inherent limitations. All of these tasks require coordination of multiple cognitive systems (visual, auditory, language, working memory) and the absence of brain response could be due to damage or lack of recruitment of one or more of these systems. The functional capacity of these systems can be influenced by anxiety and fluctuations in arousal and awareness. In addition to these caveats, fMRI data acquisition may be compromised by head motion, and interpretation of imaging data can be challenged by the presence of structural abnormalities, a temporal mismatch between presentation of the target stimulus and the patient's response, or BOLD signal characteristics different from those of healthy controls.

Information provided by fMRI and an object-naming task as an indicator of command following may be indicated particularly in cases with movement impairments. These findings, particularly in the case of VS2, indicate a clear need to consider the capacity for covert cognitive processing in addition to the overt behaviors when conducting diagnostic assessment. Determining where patients lie on the spectrum of consciousness is key to optimal clinical management, and delivery of available therapies for maximization of quality of life for this population. fMRI and the network assessment approach presented here provides additional information regard-



ing the potential cognitive capabilities of such patients, thereby offering a novel means of assessing cognitive status that cannot be documented by traditional methods.

## ACKNOWLEDGMENT

The authors thank the patients and their families for participation in the study.

## DISCLOSURE

Dr. Rodriguez Moreno has received fellowship support from the NIDRR (H133A070030). Dr. Schiff serves on a scientific advisory board for IntElect Medical, Inc.; is listed as coinventor on numerous patents re: Deep brain stimulation technology for which he receives royalties via Cornell University from IntElect Medical, Inc.; receives royalties from the publication of *Plum and Posner's Diagnosis of Stupor and Coma*, 4th ed. (Oxford University Press, 2007); and receives research support from IntElect Medical, Inc., the NIH (NINDS 1R01NS067249 [PI] and NICHD 1R01HD51912 [PI]), and the James S. McDonnell Foundation. Dr. Giacino serves on the editorial board of the *Journal of Head Trauma Rehabilitation*; has served as a training consultant for IntElect Medical, Inc.; has received research support from IntElect Medical, Inc., the NIDRR (H133A031713 [PI] and H133A070030 [Local Project PI]); and has served as an expert medico-legal consultant. Dr. Kalmar and Dr. Hirsch report no disclosures.

Received February 12, 2010. Accepted in final form July 8, 2010.

## REFERENCES

- Giacino JT, Ashwal S, Childs N, et al. The minimally conscious state: definition and diagnostic criteria. *Neurology* 2002;58:349–353.
- The Multi-Society Task Force on PVS. Medical aspects of the persistent vegetative state (1). *N Engl J Med* 1994;330:1499–1508.
- Haig AJ, Katz RT, Sahgal V. Mortality and complications of the locked-in syndrome. *Arch Phys Med Rehabil* 1987;68:24–27.
- Andrews K, Murphy L, Munday R, Littlewood C. Misdiagnosis of the vegetative state: retrospective study in a rehabilitation unit. *BMJ* 1996;313:13–16.
- Schiff ND, Rodriguez Moreno D, Kamal A, et al. fMRI reveals large-scale network activation in minimally conscious patients. *Neurology* 2005;64:514–523.
- Coleman MR, Rodd JM, Davis MH, et al. Do vegetative patients retain aspects of language comprehension? Evidence from fMRI. *Brain* 2007;130:2494–2507.
- Fernández-Espejo D, Junqué C, Vendrell P, et al. Cerebral response to speech in vegetative and minimally conscious states after traumatic brain injury. *Brain Inj* 2008;22:882–890.
- Owen AM, Coleman MR, Boly M, Davis MH, Laureys S, Pickard JD. Detecting awareness in the vegetative state. *Science* 2006;313:1402.
- Boly M, Coleman MR, Davis MH, Hampshire A, et al. When thoughts become actions: an fMRI paradigm to study volitional brain activity in non-communicative brain injured patients. *Neuroimage* 2007;36:979–992.
- Monti MM, Vanhaudenhuyse A, Coleman MR, et al. Willful modulation of brain activity in disorders of consciousness. *N Engl J Med* 2010;362:579–589.
- Bekinschtein TA, Coleman MR, Niklison J 3rd, Pickard JD, Manes FF. Can electromyography objectively detect voluntary movement in disorders of consciousness? *J Neurol Neurosurg Psychiatry* 2008;79:826–828.
- Schnakers C, Perrin F, Schabus M, et al. Voluntary brain processing in disorders of consciousness. *Neurology* 2008;71:1614–1620.
- Monti MM, Coleman MR, Owen AM. Executive functions in the absence of behavior: functional imaging of the minimally conscious state. *Prog Brain Res* 2009;177:249–260.
- Price CJ, Devlin JT, Moore CJ, Morton C, Laird AR. Meta-analyses of object naming: effect of baseline. *Hum Brain Mapp* 2005;25:70–82.
- Salmelin R, Harl R, Lounasmaa V, Sams M. Dynamics of brain activation during picture naming. *Nature* 1994;368:463–465.
- Eulitz C, Hauk O, Cohen R. Electroencephalographic activity over temporal brain areas during phonological encoding in picture naming. *Clin Neuropsychol* 2000;11:2088–2097.
- Liljestrom M, Takianinen A, Parviainen T, et al. Perceiving and naming actions and objects. *Neuroimage* 2008;41:1132–1141.
- The Quality Standards Subcommittee of the American Academy of Neurology. Practice parameters: assessment and management of patients in the persistent vegetative state (summary statement). *Neurology* 1995;45:1015–1018.
- Lemieux L, Salek-Haddadi A, Lund TE, Laufs H, Carmichael D. Modeling large motion events in fMRI studies of patients with epilepsy. *Magn Reson Imaging* 2007;25:894–901.
- Bilecen D, Radü EW, Schulte AC, et al. fMRI of the auditory cortex in patients with unilateral carotid artery steno-occlusive disease. *J Magn Reson Imaging* 2002;15:621–627.
- Hirsch J, Ruge MI, Kim KH, et al. An integrated functional magnetic resonance imaging procedure for preoperative mapping of cortical areas associated with tactile, motor, language, and visual functions. *Neurosurgery* 2000;47:711–722.
- Giacino JT, Kalmar K, Whyte J. The JFK Coma Recovery Scale: Revised: measurement characteristics and diagnostic utility. *Arch Phys Med Rehabil* 2004;85:2020–2029.
- Hirsch J, Rodriguez Moreno D, Kim KHS. Interconnected large-scale systems for three fundamental cognitive tasks revealed by fMRI. *J Cogn Neurosci* 2001;13:1–16.
- Booth JR, Burman DD, Meyer JR, Gitelman DR, Parrish TB, Mesulam MM. Functional anatomy of intra- and cross-modal lexical tasks. *Neuroimage* 2002;16:7–22.
- Okada K, Hickok G. Left posterior auditory-related cortices participate both in speech perception and speech production: neural overlap revealed by fMRI. *Brain Lang* 2006;98:112–117.
- Friederici AD, Ruschemeyer SA, Hahne A, Fiebach CJ. The role of left inferior frontal and superior temporal cortex in sentence comprehension: localizing syntactic and semantic processes. *Cereb Cortex* 2003;13:170–177.
- Burton MW. Understanding the role of the prefrontal cortex in phonological processing. *Clin Linguist Phon* 2009;23:180–195.
- Kan IP, Thompson-Schill SL. Effect of name agreement on prefrontal activity during overt and covert picture naming. *Cogn Affect Behav Neurosci* 2004;4:43–57.
- Jefferies E, Patterson K, Lambon Ralph MA. Deficits of knowledge versus executive control in semantic cognition: insights from cued naming. *Neuropsychologia* 2008;46:649–658.



30. Blank SC, Scott SK, Murphy K, Warburton E, Wise RJ. Speech production: Wernicke, Broca and beyond. *Brain* 2002;125:1829–1838.
31. Fassbender C, Hester R, Murphy K, et al. Prefrontal and midline interactions mediating behavioural control. *Eur J Neurosci* 2009;29:181–187.
32. Passingham RE. *The Frontal Lobes and Voluntary Action*. Oxford: Oxford University Press; 1995.
33. Grossberg S. How does the cerebral cortex work? Development, learning, attention, and 3-D vision by laminar circuits of visual cortex. *Behav Cogn Neurol Rev* 2003;2: 47–76.
34. Humphreys GW, Riddoch MJ, Price J. Top-down processes in object identification: evidence from experimental psychology, neuropsychology and functional neuroanatomy. *Phil Trans R Soc Lond B* 1997;352:1275–1282.
35. DeLeon J, Gottesman RF, Kleinman JT, et al. Neural regions essential for distinct cognitive processes underlying picture naming. *Brain* 2007;130:1408–1422.
36. Indefrey P, Levelt WJ. The spatial and temporal signatures of word production components. *Cognition* 2004;92: 101–144.
37. Damasio H, Tranel D, Grabowski T, Adolphs R, Damasio A. Neural systems behind word and concept retrieval. *Cognition* 2004;92:179–229.
38. Grill-Spector K, Kourtzi Z, Kanwisher N. The lateral occipital complex and its role in object recognition. *Vision Res* 2001;41:1409–1422.
39. Greenham SL, Stelmack RM, Campbell KB. Effects of attention and semantic relation on event-related potentials in a picture-word naming task. *Biol Psychol* 2000;50:79–104.

## The AAN Provides a New Resource for Your Patients

Written by Ronald DeVere, MD, Director of the Taste and Smell Disorders Clinic in Austin, Texas and Marjorie Calvert, Food Consultant at the clinic, *Navigating Smell and Taste Disorders* includes causes, treatment options, and 36 recipes and additional tips that will make food appealing again. “More than 200,000 people visit doctors each year for smell and taste problems, which often are the first sign of neurologic disorders, such as Alzheimer’s disease, Parkinson’s disease, head injury, or multiple sclerosis,” said DeVere.

“An enlightening guide. . . this patient-oriented approach should be hailed as a groundbreaking book. It is highly recommended for any patients suffering from these often undiagnosed and untreated disorders and the relatives who help care for them.”

—Alan R. Hirsch, MD, neurological director at the Smell and Taste Treatment and Research Foundation in Chicago

Invite your patients to visit [www.aan.com/view/smellandtaste](http://www.aan.com/view/smellandtaste) for more information about this invaluable resource. Available from all major booksellers.

**A network approach to assessing cognition in disorders of consciousness**  
D. Rodriguez Moreno, N.D. Schiff, J. Giacino, et al.  
*Neurology* 2010;75;1871-1878 Published Online before print October 27, 2010  
DOI 10.1212/WNL.0b013e3181feb259

**This information is current as of October 27, 2010**

<b>Updated Information &amp; Services</b>	including high resolution figures, can be found at: <a href="http://www.neurology.org/content/75/21/1871.full.html">http://www.neurology.org/content/75/21/1871.full.html</a>
<b>Supplementary Material</b>	Supplementary material can be found at: <a href="http://www.neurology.org/content/suppl/2010/10/28/WNL.0b013e3181feb259.DC1.html">http://www.neurology.org/content/suppl/2010/10/28/WNL.0b013e3181feb259.DC1.html</a>
<b>References</b>	This article cites 38 articles, 11 of which you can access for free at: <a href="http://www.neurology.org/content/75/21/1871.full.html##ref-list-1">http://www.neurology.org/content/75/21/1871.full.html##ref-list-1</a>
<b>Citations</b>	This article has been cited by 2 HighWire-hosted articles: <a href="http://www.neurology.org/content/75/21/1871.full.html##otherarticles">http://www.neurology.org/content/75/21/1871.full.html##otherarticles</a>
<b>Subspecialty Collections</b>	This article, along with others on similar topics, appears in the following collection(s): <b>All Ethics in Neurology/Legal issues</b> <a href="http://www.neurology.org/cgi/collection/all_ethics_in_neurology_legal_issues">http://www.neurology.org/cgi/collection/all_ethics_in_neurology_legal_issues</a> <b>Assessment of cognitive disorders/dementia</b> <a href="http://www.neurology.org/cgi/collection/assessment_of_cognitive_disorders_dementia">http://www.neurology.org/cgi/collection/assessment_of_cognitive_disorders_dementia</a> <b>Brain trauma</b> <a href="http://www.neurology.org/cgi/collection/brain_trauma">http://www.neurology.org/cgi/collection/brain_trauma</a> <b>fMRI</b> <a href="http://www.neurology.org/cgi/collection/fmri">http://www.neurology.org/cgi/collection/fmri</a>
<b>Permissions &amp; Licensing</b>	Information about reproducing this article in parts (figures, tables) or in its entirety can be found online at: <a href="http://www.neurology.org/misc/about.xhtml#permissions">http://www.neurology.org/misc/about.xhtml#permissions</a>
<b>Reprints</b>	Information about ordering reprints can be found online: <a href="http://www.neurology.org/misc/addir.xhtml#reprintsus">http://www.neurology.org/misc/addir.xhtml#reprintsus</a>

